

# Inferior base Nasolabial Flap in Oral submucous Fibrosis: case report

Ankur Rathaur, Prasanna Kumar P, Ankita Raj, Aathira Madhu, Akash Tiwari, Tuba Jamal

Rama Dental College Hospital & Research Centre, Rama University, Mandhana, Kanpur, Uttar Pradesh- India 209217

---

## ABSTRACT

Oral submucous fibrosis (OSMF) is a chronic, insidious, progressive oral mucosal disease affecting the oral cavity, pharynx, and upper digestive tract, causing stiffness of the oral mucosa, restricted mouth opening, and impaired ability to eat, speak or care for oral hygiene. Serious complication is the risk of development of oral carcinoma. Different treatment modalities like medical, surgical, physical therapy or combination are used to improve the condition of the patient. Surgical treatment is usually indicated in late and irreversible stage of the disease. Successful use of nasolabial flap in the management of OSMF is presented.

---

## INTRODUCTION

Schwartz coined the term “atrophica idiopathica mucosa oris” to describe an oral fibrosing disease. He observed same in five Indian women from Kenya. Later on Joshi termed the condition oral submucous fibrosis. Oral submucous fibrosis (OSMF) is defined as “an insidious chronic disease affecting any part of the oral cavity and sometimes the pharynx”. It is always associated with juxta-epithelial inflammatory reaction followed by fibroelastic changes of the lamina propria with epithelial atrophy leading to stiffness of the oral mucosa and causing trismus and inability to speak”. It is considered as a ‘pre-malignant condition’. The disease is more prevalent in Indian subcontinent. Oral submucous fibrosis is widely prevalent in all age groups and across all socioeconomic strata in India.

The etiology of OSMF is still unclear, although multiple factors have been implicated in its development. Such factors are areca nut chewing, high chili consumption, genetic, immunological, and nutritional deficiencies, etc. Therefore, there is no definitive treatment. The main aim of the treatment is to relieve symptoms, prevent cancer initiation and improve mouth opening. Surgical treatment is usually indicated in late and irreversible stage. It consists of release of fibrous bands followed by use of various grafts. In 1830, Dieffenbach first used superiorly based nasolabial flaps to reconstruct nasal alae. Nasolabial flap is reliable and economical option for the surgical management of OSMF.<sup>5</sup> Here, we are presenting a case of OSMF successfully treated by nasolabial flap with 6 months follow-up.

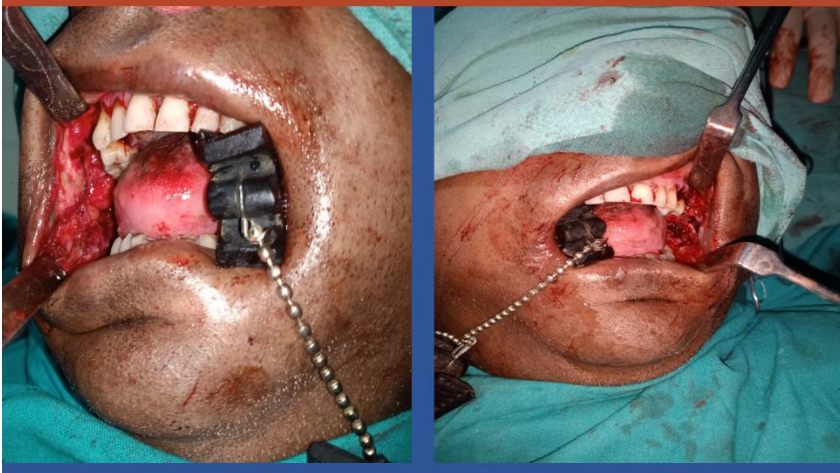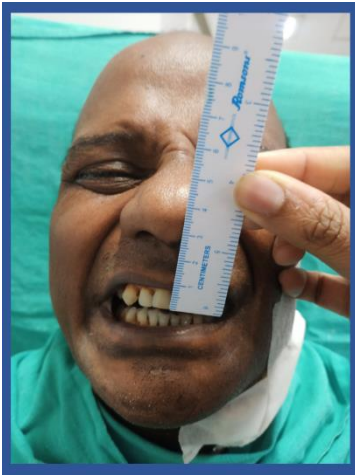## CASE REPORT

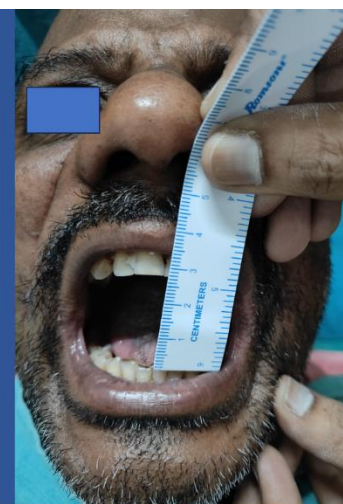
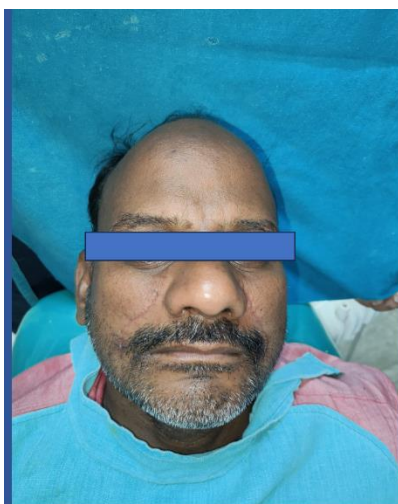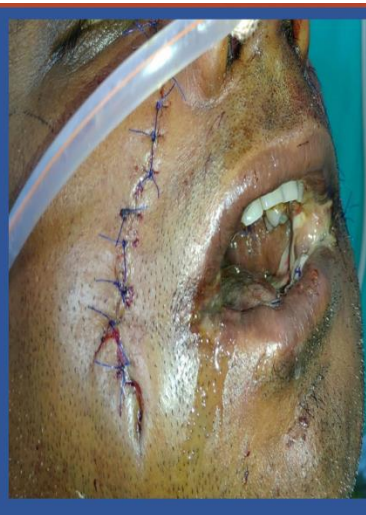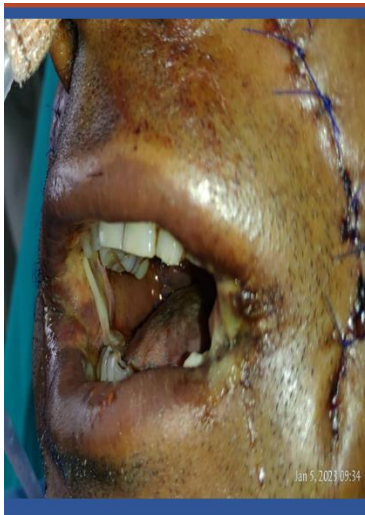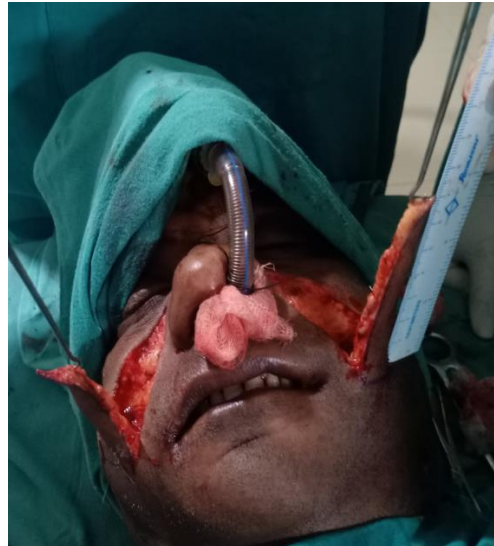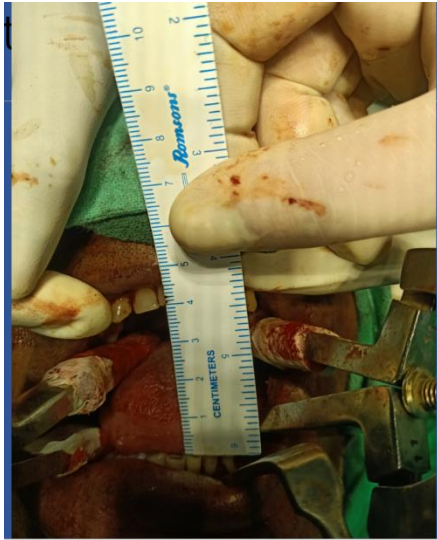A 42 years old male reported with reduced mouth opening since 6 years. Interincisal distance was less than 3mm. Blanching of mucosa was seen and fibrotic bands were palpated bilaterally involving buccal mucosa and retromolar trigone region. Provisional diagnosis of late stage OSMF given. Patient was informed about the pre-malignant nature of the condition and importance of functional mouth opening. Inferiorly based nasolabial flap was planned for surgical mouth opening.

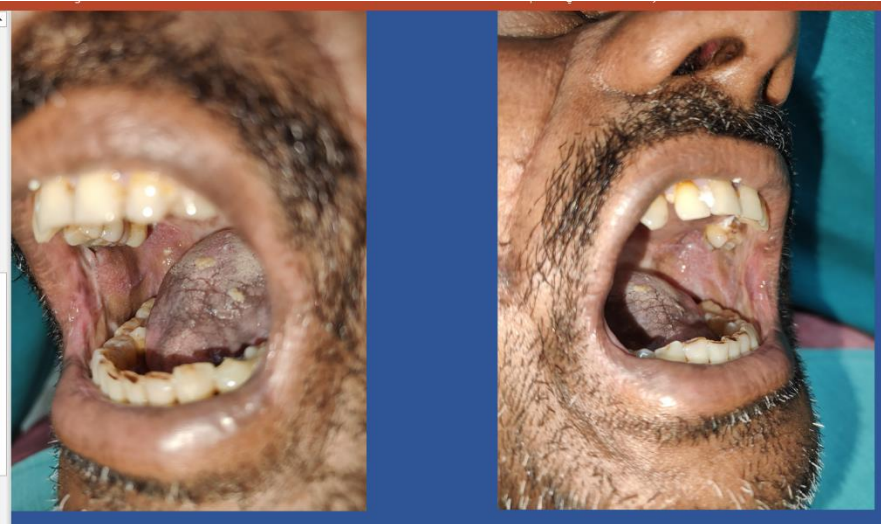The surgery was performed under general anesthesia with fiberoptic nasal intubation. An intraoral incision is made in the buccal mucosa at the level of occlusal plane, 1 cm away from the corner of the mouth to anterior faucial pillars to cut the fibrous bands in the cheek mucosa. The interincisal distance

was increased around 3cm immediately after release of fibrous bands. Coronoidectomy with temporal myotomy was performed. Nasolabial flaps from the tip of nasolabial fold to corner of mouth were marked bilaterally. Both flaps were raised in the plane of the superficial musculoaponeurotic system. The flap was transposed intraorally through a small transbuccal tunnel near the commissure of the mouth, with no tension and the caudal base of the inferiorly base

d nasolabial flap was deepithelialized in a triangular fashion. The area of deepithelialization is determined by the area of the defect and so the prepared area for the transbuccal tunnel. Transbuccal tunnel has to be completely covered by the flap. This is the important step of the procedure. The extraoral defect was closed primarily in layers after undermining skin in subcutaneous plane to prevent tension across the suture line. Patient was advised for mouth opening exercises from 4th postoperative day and to continue same for minimum 6 to 8 months in order to prevent relapse. Six months postoperation interincisal distance was 3 cm. There were no further reduction in mouth opening and recurrence of the condition.







## DISCUSSION

Oral submucous fibrosis is a unsatisfactorily treated disease. Surgical treatment usually aims to relieve trismus, involves incising and releasing the fibrotic areas followed with or without grafting. Various surgical treatments have been proposed by different authors. Each modality has its own advantages and disadvantages. A mucosal graft may be the ideal treatment for oral submucous fibrosis, but is limited in quantity. It can be used for smaller defects.

Release of fibrous bands and split thickness skin grafting has a high recurrence from contracture. The survival of full thickness skin grafts is questionable. Esthetics and function achieved with split skin graft were good but showed some degree of relapse due to contracture of the graft. Borle and Borle reported disappointing results with skin grafting to cover the raw area and used tongue flap to cover the defect. Tongue flaps cause severe dysphasia, disarticulation, and carry the risk of postoperative aspiration, instability and dehiscence are the common postoperative complication. In addition, tongue is itself involved in the disease process in some cases. Even though buccal fat pad is found successful in some studies, main drawback is its limited size and cannot be used for larger defects. However, nasolabial flap can be used to close large defects. It has an edge of close proximity to defect, easily accessibility and modifiable with single sitting surgery resulting in a camouflaged scar. Complications include intraoral hair growth and loss of nasomaxillary crease. A periosteal suture can be used to recreate the crease. Nasolabial flap has been successfully used in the management of OSMF-induced trismus. In our case, patient was satisfied with the treatment with minor complaint of surgical scar.

## CONCLUSION

Inferiorly based nasolabial flap can be used to treat severe trismus and larger defects of OSMF origin.

1. Oral submucous fibrosis: Current concepts on aetiology and management - A review. Khan S, Sinha A, Kumar S, Iqbal H. *J Indian Acad Oral Med Radiol.* 2018;30:407–411.



2. An alternative pathogenetic pathway for oral submucous fibrosis (OSMF)  
Rajendran R, Vijayakumar T, Vasudevan DM. *Med Hypotheses*. 1989;30:35–37. [
3. Increased severity of oral submucous fibrosis in young Pakistani men. Merchant AT, Haider SM, Fikree FF. *Br J Oral Maxillofac Surg*. 1997;35:284–287.
4. Betel quid without tobacco as a risk factor for oral precancers. Jacob BJ, Straif K, Thomas G, et al. *Oral Oncol*. 2004;40:697–704. [
5. Stimulation of human buccal mucosa fibroblasts in vitro by betel-nut alkaloids. Harvey W, Scutt A, Meghji S, Canniff JP. *Arch Oral Biol*. 1986;31:45–49.
6. An in-vitro comparison of human fibroblasts from normal and oral submucous fibrosis tissue. Meghji S, Scutt A, Harvey W, Canniff JP. *Arch Oral Biol*. 1987;32:213–215. .
7. Immunolocalization of cytokines and growth factors in oral submucous fibrosis. Haque MF, Harris M, Meghji S, Barrett AW. *Cytokine*. 1998;10:713–719. .
8. Augmented mRNA expression of tissue inhibitor of metalloproteinase-1 in buccal mucosal fibroblasts by arecoline and safrole as a possible pathogenesis for oral submucous fibrosis. Shieh DH, Chiang LC, Shieh TY. *Oral Oncol*. 2003;39:728–735. .
9. Oral submucous fibrosis. A review. Cox SC, Walker DM. *Aust Dent J*. 1996;41:294–299. .
10. Increased tissue inhibitor of metalloproteinase-1 expression and inhibition of gelatinase A activity in buccal mucosal fibroblasts by arecoline as possible mechanisms for oral submucous fibrosis. Chang YC, Yang SF, Tai KW, Chou MY, Hsieh YS. *Oral Oncol*. 2002;38:195–200. .
11. Oral submucous fibrosis: review on mechanisms of malignant transformation. Ekanayaka RP, Tilakaratne WM. *Oral Surg Oral Med Oral Pathol Oral Radiol*. 2016;122:192–199. .
12. Current protocols in the management of oral submucous fibrosis: An update. Arakeri G, Rai KK, Boraks G, et al. *J Oral Pathol Med*. 2017;46:418–423. .
13. Oral submucous fibrosis. Pindborg JJ, Sirsat SM. *Oral Surg Oral Med Oral Pathol*. 1966;22:764–779. .
14. Etiology of oral submucous fibrosis with special reference to the role of areca nut chewing. Murti PR, Bhonsle RB, Gupta PC, Daftary DK, Pindborg JJ, Mehta FS. *J Oral Pathol Med*. 1995;24:145–152. .
15. Oral submucous fibrosis: review on aetiology and pathogenesis. Tilakaratne WM, Klinikowski MF, Saku T, Peters TJ, Warnakulasuriya S. *Oral Oncol*. 2006;42:561–568. .
16. Interferon gamma (IFN-gamma) may reverse oral submucous fibrosis. Haque MF, Meghji S, Nazir R, Harris M. *J Oral Pathol Med*. 2001;30:12–21. .

17. Aloe vera in treatment of oral submucous fibrosis: A systematic review and meta-analysis. Al-Maweri SA, Ashraf S, Lingam AS, Alqutaibi A, Abdulrab S, Alaizari N, Halboub E. *J Oral Pathol Med.* 2019;48:99–107. .
18. Possible action mechanism for curcumin in pre-cancerous lesions based on serum and salivary markers of oxidative stress. Rai B, Kaur J, Jacobs R, Singh J. *J Oral Sci.* 2010;52:251–256. .
19. An approach to management of oral submucous fibrosis: current status and review of literature. Fry RR, Goyal S, Pandher PK, Chawla JP. <http://journalcra.com/sites/default/files/issue-pdf/7001.pdf> *Int J Curr Res.* 2014;6:10598–10604. [[Google Scholar](#)]
20. Treatment of oral submucous fibrosis with ErCr: YSGG laser. Chaudhary Z, Verma M, Tandon S. <https://www.ijdr.in/text.asp?2011/22/3/472/87073>. *Indian J Dent Res.* 2011;22:472–474. .
21. Oral submucous fibrosis: Newer proposed classification with critical updates in pathogenesis and management strategies. Passi D, Bhanot P, Kacker D, Chahal D, Atri M, Panwar Y. *Natl J Maxillofac Surg.* 2017;8:89–94. [[PMC free article](#)] .
22. Oral submucous fibrosis as a precancerous condition. Pindborg JJ, Murti PR, Bhonsle RB, Gupta PC, Daftary DK, Mehta FS. *Scand J Dent Res.* 1984;92:224–229. .
23. Malignant transformation rate in oral submucous fibrosis over a 17-year period. Murti PR, Bhonsle RB, Pindborg JJ, Daftary DK, Gupta PC, Mehta FS. *Community Dent Oral Epidemiol.* 1985;13:340–341. .
24. Proposed clinical classification for oral submucous fibrosis. More CB, Das S, Patel H, Adalja C, Kamatchi V, Venkatesh R. *Oral Oncol.* 2012;48:200–202. .
25. Oral submucous fibrosis: a new concept in surgical management. Report of 100 cases. Khanna JN, Andrade NN. *Int J Oral Maxillofac Surg.* 1995;24:433–439. .
26. Salivary copper and zinc levels in oral pre-malignant and malignant lesions. Ayinampudi BK, Narsimhan M. *J Oral Maxillofac Pathol.* 2012;16:178–182. [[PMC free article](#)] .
27. Oral submucosal fibrosis--a preventable disease. Jayanthi V, Probert CS, Sher KS, Mayberry JF. *Gut.* 1992;33:4–6. [[PMC free article](#)] .
28. Incidence and early forms of oral submucous fibrosis. Pindborg JJ, Bhonsle RB, Murti PR, Gupta PC, Daftary DK, Mehta FS. *Oral Surg Oral Med Oral Pathol.* 1980;50:40–44. .
29. Malignant transformation of oral submucous fibrosis in Taiwan: A nationwide population-based retrospective cohort study. Yang PY, Chen YT, Wang YH, Su NY, Yu HC, Chang YC. *J Oral Pathol Med.* 2017;46:1040–1045..
30. Treatment of oral submucous fibrosis by collagenase: effects on oral opening and eating function. Lin HJ, Lin JC. *Oral Dis.* 2007;13:407–413. .

31. Oral submucous fibrosis: study of 1000 cases from central India. Hazarey VK, Erlewad DM, Mundhe KA, Ughade SN. *J Oral Pathol Med.* 2007;36:12–17. .
32. Oral submucous fibrosis patients have altered levels of cytokine production. Haque MF, Meghji S, Khitab U, Harris M. *J Oral Pathol Med.* 2000;29:123–128. .
33. Aloe vera in the treatment for oral submucous fibrosis - a preliminary study. Sudarshan R, Annigeri RG, Sree Vijayabala G. *J Oral Pathol Med.* 2012;41:755–761. .
34. Curcumin in oral mucosal lesions: An update. Rai A, Kumar A, Hasan S, Saeed S. *Asian J Pharm Clin Res.* 2019;12:32–43. [[Google Scholar](#)]
35. Pentoxifylline therapy: a new adjunct in the treatment of oral submucous fibrosis. Rajendran R, Rani V, Shaikh S. <https://www.ijdr.in/text.asp?2006/17/4/190/29865>. *Indian J Dent Res.* 2006;17:190–198. .
36. Oral submucous fibrosis--a new treatment regimen. Gupta D, Sharma SC. *J Oral Maxillofac Surg.* 1988;46:830–833. .
37. Oral submucous fibrosis--treatment with hyalase. Kakar PK, Puri RK, Venkatachalam VP. *J Laryngol Otol.* 1985;99:57–59. .
38. Management of oral submucous fibrosis: an overview. Angadi PV, Rao S. *Oral Maxillofac Surg.* 2010;14:133–142..
39. Is buccal fat pad a better option than nasolabial flap for reconstruction of intraoral defects after surgical release of fibrous bands in patients with oral submucous fibrosis? A pilot study: a protocol for the management of oral submucous fibrosis. Rai A, Datarkar A, Rai M. *J Craniomaxillofac Surg.* 2014;42:0–6. .
40. Oral submucous fibrosis: a clinico-histopathological study in Chennai. Kiran Kumar K, Saraswathi TR, Ranganathan K, Uma Devi M, Elizabeth J. *Indian J Dent Res.* 2007;18:106–111. .
41. Clinical evaluation of Er,Cr:YSGG and GaAlAs laser therapy for treating dentine hypersensitivity: A randomized controlled clinical trial. Yilmaz HG, Kurtulmus-Yilmaz S, Cengiz E, Bayindir H, Aykac Y. *J Dent.* 2011;39:249–254..
42. Autologous bone marrow concentrate (Mononuclear Stem Cell) therapy in the treatment of oral submucous fibrosis. Seshadri S, Kailasam S, Elangovan S, Ravi VR, Sarkar S. *J Indian Acad Oral Med Radiol.* 2013;25:1–4. [[Google Scholar](#)]
43. Oncogene amplification in squamous cell carcinoma of the oral cavity. Saranath D, Panchal RG, Nair R, et al. *Jpn J Cancer Res.* 1989;80:430–437. [[PMC free article](#)] .
44. Ras mutations in United Kingdom examples of oral malignancies are infrequent. Chang SE, Bhatia P, Johnson NW, Morgan PR, McCormick F, Young B, Hiorns L. *Int J Cancer.* 1991;48:409–412. .

45. A transforming Kirsten ras oncogene in an oral squamous carcinoma. Howell RE, Wong FS, Fenwick RG. *J Oral Pathol Med.* 1990;19:301–305. .
46. Depigmentation of oral mucosa as the earliest possible manifestation of oral submucous fibrosis in Sri Lankan preschool children. Sitheequ M, Ariyawardana A, Jayasinghe R, Tilakaratne W. *J Investig Clin Dent.* 2010;1:156–